

## Congenital Megacolon: morfofunctional remainings on rat colon after benzalkonium chloride treatment

Caroline Judeikis\*, Joaquim M. B. Silva, Marcia A. C. P. da Silva.

### Abstract

Hirschsprung's disease is characterized by colonic aganglionosis, affecting mainly newborns. The current treatment of this pathology is surgical, but several studies are underway to develop less invasive methods that could cause less comorbidities. These studies use congenital megacolon models, one of which uses benzalkonium chloride to cause neurogenic ablation. The objective of this study is to demonstrate the effectiveness of aganglionosis provided by this drug by describing the remaining cells after denervation in order to optimize studies that use this model later.

**Key words:** *Hirschsprung's disease, congenital megacolon model, benzalkonium chloride.*

### Introduction

Hirschsprung's disease affects mostly newborns, in the proportion of one in 5,000 children, and is considered relatively common. It is characterized by distal colon aganglionosis due to genetic signaling failures during enteral neuronal colonization. Main symptoms consist of constipation and delay to eliminate meconium, more often pointing to an early diagnosis.

The treatment of this pathology is essentially surgical, however, 60% of the patients present complications after surgery, such as fecal incontinence, enterocolitis or even death. Due to this, there are several researches focused on the development of less invasive treatments. Many of these depend on congenital megacolon models, one of which is obtained by using benzalkonium chloride to provide neuronal ablation (first description of this model was made by Sato et Cols in 1978).

The ablation provided by the benzalkonium chloride has limitations due to divergences involving the effectiveness of the denervation obtained. The objective of this study is to investigate the effectiveness of the aganglionosis provided by this drug through the analysis of the remaining cells after treatment, to optimize later studies that use this model.

### Results and Discussion

For this study, animal models of Wistar rats were used; the animals were submitted to the surgical procedure described by Dunn et al in 2014, which consists of a median laparotomy with exteriorization of the descending colon.

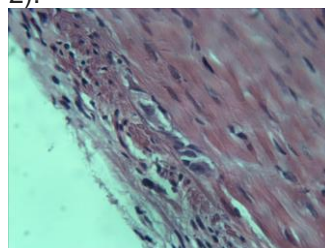
Part from colon (about two cm) was isolated from intestinal transit, washed with 0.9% NaCl and closed at its extremities. The intestinal transit was reestablished with a termino-terminal anastomosis. The isolated colon segment was treated with gauze soaked with 0.02% benzalkonium chloride for 20 minutes, washed with 0.9% NaCl and the abdominal wall was closed.

Thirty days after the procedure the animals were sacrificed and samples of normal colon (control) and colonic treated segment (test) were harvested for histological analysis.

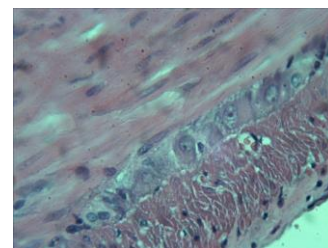
In the samples treated (tests) with benzalkonium chloride, neuronal cells were visualized with retraction and vacuolization of the cytoplasm, nuclei with irregular

contour and chromatin condensation, without evident nucleolus (Figure 1).

In normal colon samples (controls), cells with a larger volume of cytoplasm, presenting mild to moderate basophilia, bulky nuclei with a regular contour, loose chromatin and evident nucleolus were observed (Figure 2).



**Image 1.** Test sample.



**Image 2.** Control sample.

It is noted, therefore, that benzalkonium chloride promotes what appears to be the lysis of neuronal cells, but there are remains of the same in the tissue.

### Conclusions

Analyzing the samples treated with benzalkonium chloride already obtained from the animal models, we can conclude that there is still some neural material present in the tissue, but probably not functional, since it has different characteristics from the functional cells observed in the unaltered samples, suggesting possible cellular damage. We also conclude that the analysis of the next samples to will require the use of specific markers for neuronal and glial cells to determine the remaining cell types and the types most injured by the treatment.

### Acknowledgement

I thank CNPq, CEUA Unicamp, the team of the Nucleus of Medicine and Experimental Surgery, to my supervisor in this project Prof. Dr. Joaquim Murray Busttorff-Silva and my collaborator Dr. Marcia Alessandra Cavalaro Pereira da Silva for the opportunity to develop this project and for the learning that it brought me.

<sup>1</sup>Yamamoto M, Imamura K, et al. Pathophysiology of aganglionic colon and anorectum: an experimental study on aganglionosis produced by a new method in the rat. *J Pediatric Surgery* 13 (1978) 399–405.

<sup>2</sup>Justin P. Wagner, Veronica F. Sullins, Hassan A. Khalil, James C.Y. Dunn, et al. A durable model of Hirschsprung's colon. *J Pediatric Surgery* 49 (2014) 1804–1808.