



Pharmacoresistant seizures associate with widespread cortical thickness atrophy in temporal lobe epilepsy

Lucas L. Montanher*, Letícia F. Ribeiro, Fernando Cendes, Clarissa L. Yasuda

Abstract

Temporal Lobe Epilepsy (TLE) is the most common epileptic syndrome in adults, and also the most resistant to clinical treatment. Several studies were designed to study brain impacts from focal epilepsies. Surface Based Morphometry (SBM) is a well-validated analytical procedure used to quantify cortical thickness and other parameters in MRI. In the present study, we evaluated cortical involvement in TLE patients in function of seizures control.

Key words:

Temporal lobe epilepsy, surface-based morphometry, seizure control

Introduction

Temporal Lobe Epilepsy (TLE), a subtype of focal type epilepsy, is the most common epileptic syndrome in adults, affecting around 1% of the world population¹, and also the most resistant to clinical treatment, with the highest rate of drug-resistant patients². However, few studies have evaluated the impact of seizure control on brain's atrophy. In the present study, we evaluated cortical involvement in TLE patients in function of disease severity and seizure control using the Surface Based Morphometry (SBM) method, a well-validated analytical procedure used to quantify cortical thickness and other parameters in MRI.

Results and Discussion

We analysed the T1-weighted 3T MRI images of 198 TLE patients who were divided into three groups according to seizure control (refractory: 94; fluctuating: 75; seizure free: 29). A control group of 223 healthy subjects paired for age ($p=0.78$) and sex ($p=0.49$) was used for comparisons. We performed cortical thickness analyses using the CAT12 toolbox/spm12 (<http://www.neuro.uni-jena.de/cat/>). All images were submitted to preprocessing including normalisation, segmentation into grey and white matter and cerebrospinal fluid maps and smoothing. Afterwards, we extracted the cortical thickness values using Surface-Based Morphometry (SBM) and performed T-tests between the control group and each group of patients searching for areas of cortical thickness atrophy. Significant results were reported after Bonferroni correction ($p<0.05$, FWE corrected).

We did not identify any areas of cortical atrophy in the **seizure-free group**. The **fluctuating group** presented small clusters of bilateral cortical atrophy mainly in the posterior parietal and occipital regions. The **refractory group**, on contrary, presented widespread areas of thickness atrophy, especially in the frontal and temporal lobes.

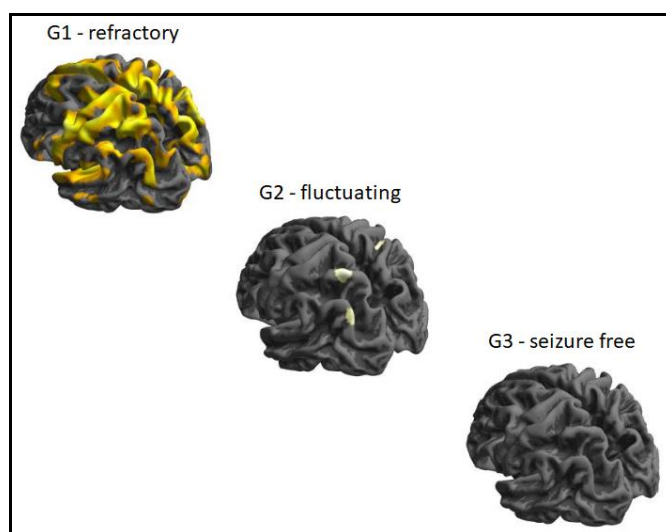


Image: The figures represent, in a color spectrum from gray to red, the areas and intensity of cortical thickness atrophy of the TLE patients relative to the corresponding group of healthy controls.

Conclusions

Our results suggest a negative impact of pharmacoresistant seizures on cortical thickness. The worse seizure control appears to be related to more widespread cortical atrophy.

In the next step of the research, we will try to correlate these results with the previous study of voxel-based morphometry, in the search for possible patterns of atrophy according to the different seizures control.

Acknowledgement

This research was performed at the Neuroimaging Laboratory at HC-Unicamp, and funded by PIBIC - CNPq, CEPID-BRAINN (FAPESP) 2013/07559-3

¹ - Long, H.Y., et al. Blood DNA methylation pattern is altered in mesial temporal lobe epilepsy. *Sci Rep.* 2017, 9:7:43810;

² - Coyle, A., et al. From resection to ablation: A review of resective surgical options for temporal lobe epilepsy and rationale for an ablation-based approach. *Neurol India.* 2017, 65(Supplement):S71-S77;