

Cerebellar atrophy in Neuromyelitis Optica Spectrum Disease (NMOSD) patients

Souza, Rodrigo F. S. *; Von Glehn, Felipe; Santos, MLB; Cendes, Fernando; Yasuda, Clarissa L.

Abstract

Neuromyelitis Optica Spectrum Disease (NMOSD) is an autoimmune neurodegenerative process which affects the optic nerve and spinal cord in inflammatory outbreaks, leading to its symptoms. Newly, recent studies have showed that other structures in central nervous system (CNS), like the brain cortex, thalamus and medulla oblongata are affected too. The increased use of different techniques of magnetic resonance imaging (MRI) analysis, such the voxel-based morphometry (VBM), has improved our knowledge about the real CNS damage in NMOSD patients.

Key words:

Neuromyelitis Optica, NMOSD, Cerebellum, VBM.

Introduction

Neuromyelitis optica (NMO) is a rare autoimmune neurodegenerative disease, which severely compromises the patients affected, mainly in the regions of the optic nerve and the spinal cord. Being a disorder that occurs in inflammatory outbreaks, often the full manifestation characteristics of NMO is not observed initially. Thus, the term Neuromyelitis Optica Spectrum Diseases (NMOSD) is used to designate the variety of clinical conditions that can occur in patients, without fulfilling the criteria for NMO, but still with a similar etiology to this disease.

The classic lesions caused by NMOSD are widely described. However, new studies show that, in addition to those, other areas of the CNS are affected. Thereby, findings of cerebellar involvement in this group of patients may be expected. Therefore, the project described below aims to compare the different cerebellar areas of individuals with NMOSD versus a control group, and it is our hypothesis that the affected group present significant cerebellar atrophies.

Results and Discussion

Thirty-nine NMOSD AQP4-IgG positive patients from UNICAMP's Neurology Service were selected to participate in this study; fifteen of these patients presented neuromyelitis optica (NMO), nine presented longitudinally extensive transverse myelitis (LETM) and eight are diagnosed with optic neuritis only. For group comparisons, forty-two healthy controls were selected from an MRI bank of healthy volunteers. Images were acquired at Hospital de Clínicas (UNICAMP) using a 3 Tesla Achieva-Intera Philips MRI scanner including 3D-T1 weighted images (isotropic voxels of 1 mm³, acquired in the sagittal plane; 1 mm thick, flip angle=80, TR= 7ms, TE 3,2ms, FOV= 240 x 240 x 180 mm³). All images were segmented according to standard SPM12/CAT12 and SUIT6 protocols (<http://www.neuro.uni-jena.de/cat/>) (www.fil.ion.ucl.ac.uk)

(<http://www.diedrichsenlab.org/imaging/suit.htm>), which included: spatial normalization, cerebellum segmentation and smoothing, Quality control of image segmentation was performed. Statistical analysis of images was performed with SPM12, while clinical information was compared with GraphPad Prism 7.

NMOSD and control were paired by gender and age. The figure below shows significant cerebellar cortical

atrophy in NMOSD patients compared to healthy controls ($p < 0.05$).

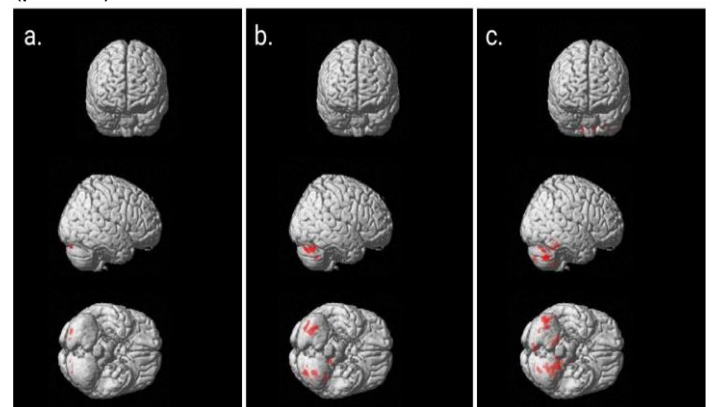


Image 1. Distribution of cerebellar cortical atrophy in NO (a), LETM (b) and NMO (c) patients. Both cerebellar hemispheres and vermis are affected.

Cerebellar cortical atrophy observed in patients group confirms the recent studies results', in which other areas of CNS than the classic ones are affected by NMOSD. It is possible that these findings occurs due to direct immunomediated lesions or by a secondary degeneration mechanism in areas interconnected in the CNS

Conclusions

Cerebellar atrophy can be seen in NMOSD patients, especially in the ones who present LETM or NMO. Further studies of clinical symptoms in these patients or using other MRI techniques may reveal the complete clinical meaning of these findings.

Acknowledgement

PIBIC/CNPq

Brazilian Institute of Neuroscience and Neurotechnology - BRAINN

- [1] Wingerchuk, D. M. et al. *Neurology* 85, 177–189 (2015);
- [2] Glehn, F. Von et al. *Mult. Scler. J.* (2014).;
- [3] Whittam, D. et al. *J. Neurol.* (2017).
- [4] Duan, Y., Liu, Y., Liang, P. & Jia, X. *Acta radiol.* 55, 589–593 (2014);
- [5] Chen, C. et al. *Acta Acad. Med. Sin.* 36, 432–438 (2014).
- [6] Diedrichsen, J. *Neuroimage* 33, 127–138 (2006).